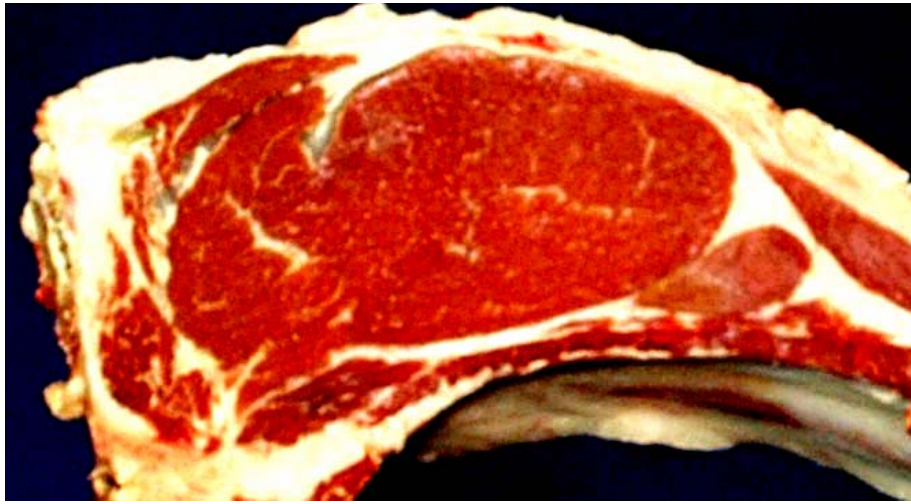


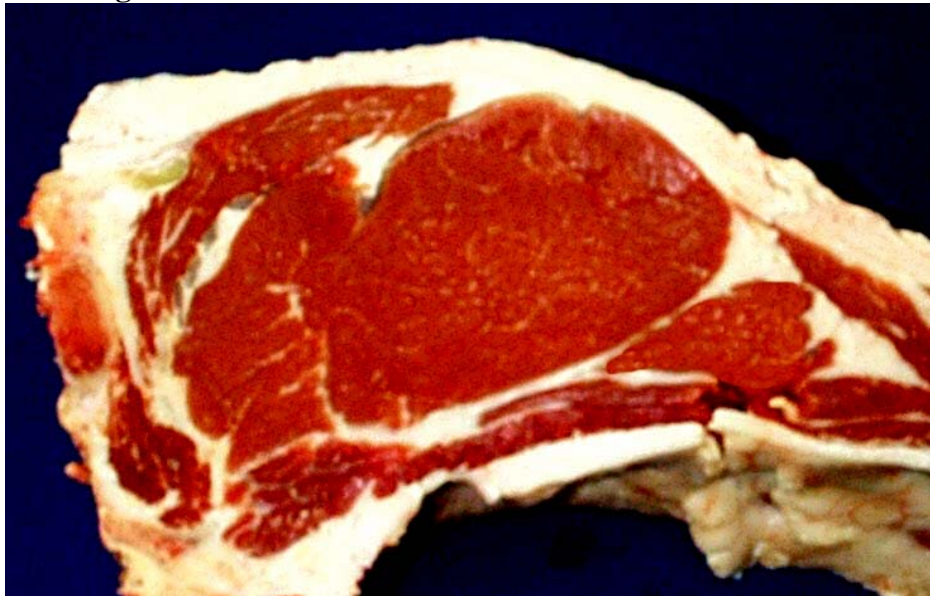
## **Carcass Measurements**

**Figures 1A, 1B, 1C** and **Figures 2A, 2B, 2C** compare the carcass cross-sections with the ultrasound images starting at the 12-13<sup>th</sup> rib juncture (where a carcass side is separated into the fore and hind quarter) and moving forward one rib at a time. Muscle shape and size changes are discussed in the Anatomy section (p.1-14).

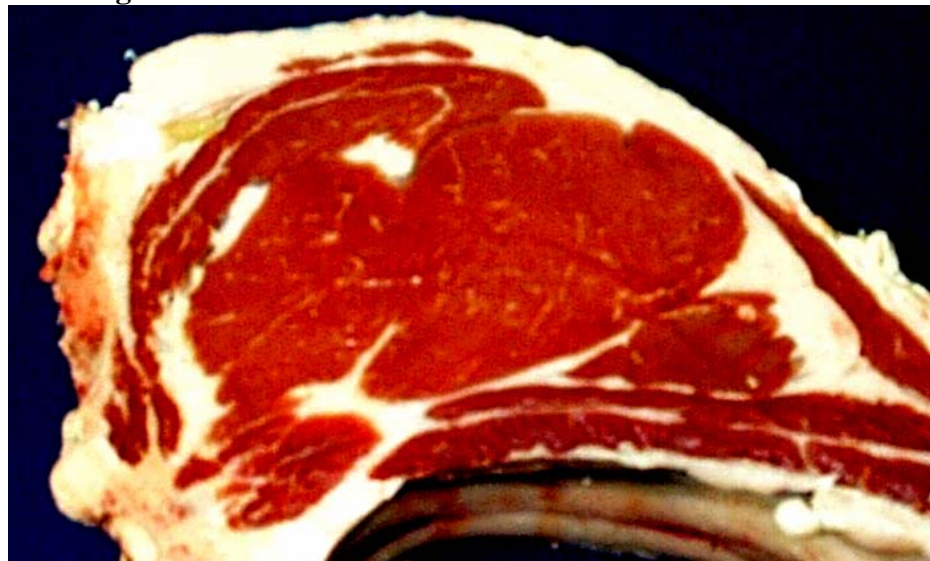**Figures 3A, 3B** and **Figures 4A, 4B** compare carcass cross-sections and ultrasound images moving in a posterior direction from the 12-13<sup>th</sup> rib. **Figure 3C** relates the carcass cross-section between the 1<sup>st</sup>-2<sup>nd</sup> lumbar vertebrae. Labels outlining important ultrasound scanning landmarks can be located on **Figure 5A**.



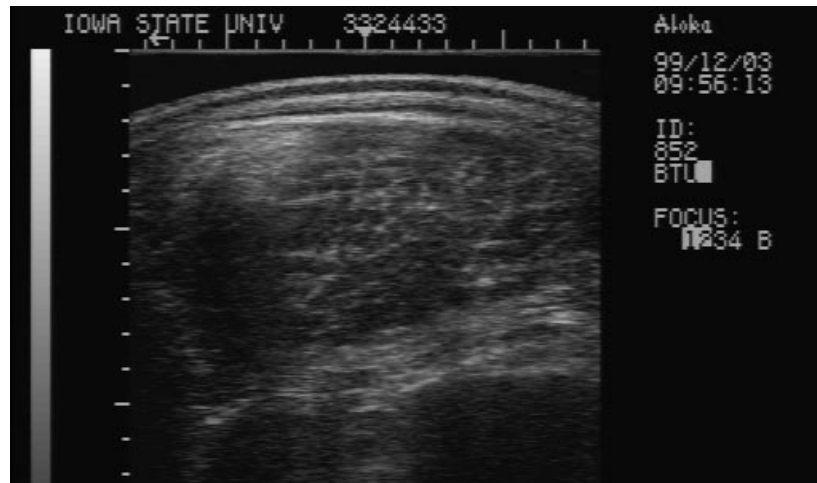
**Figure 1A.** 12-13<sup>th</sup> rib carcass cross-section



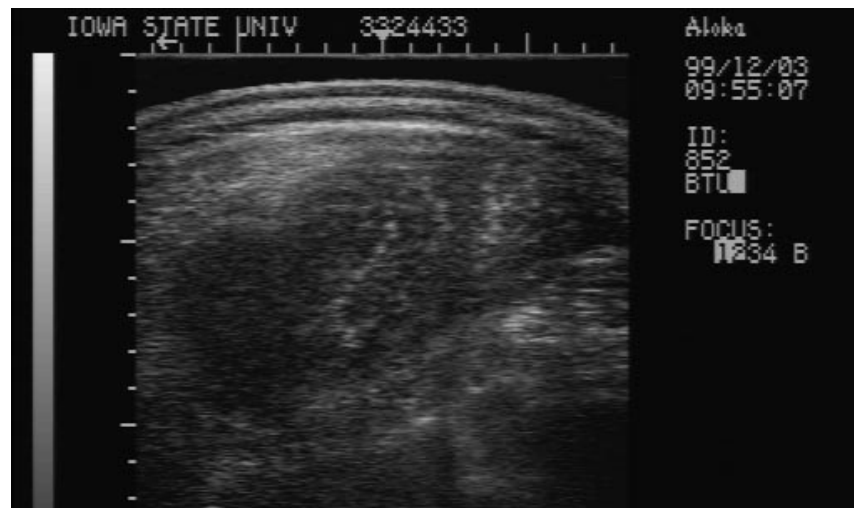
**Figure 1B.** 11-12<sup>th</sup> rib carcass cross-section



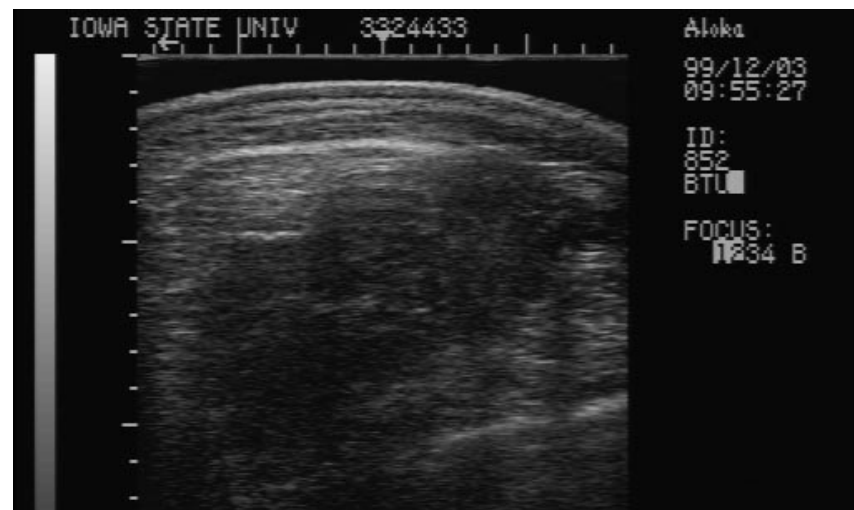
**Figure 1C.** 10-11<sup>th</sup> rib carcass cross-section



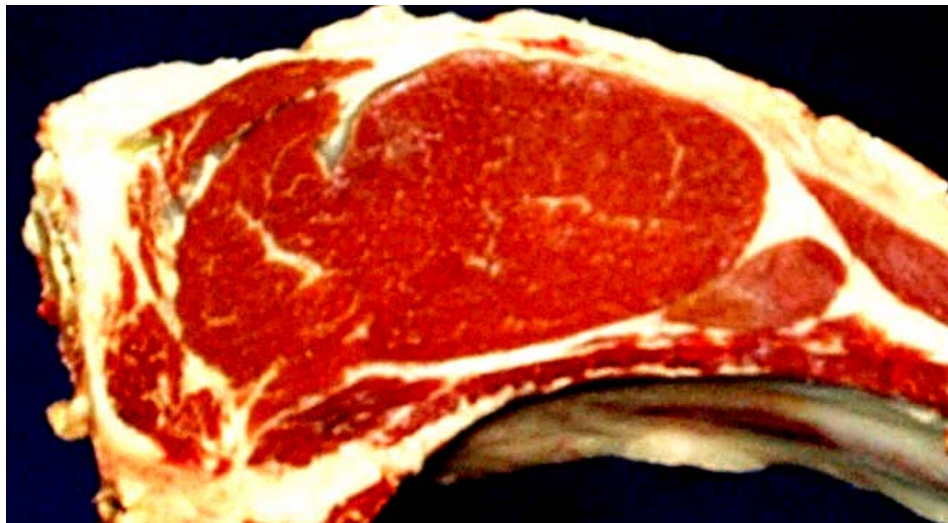
**Figure 2A.** 12-13<sup>th</sup> rib cross-sectional image



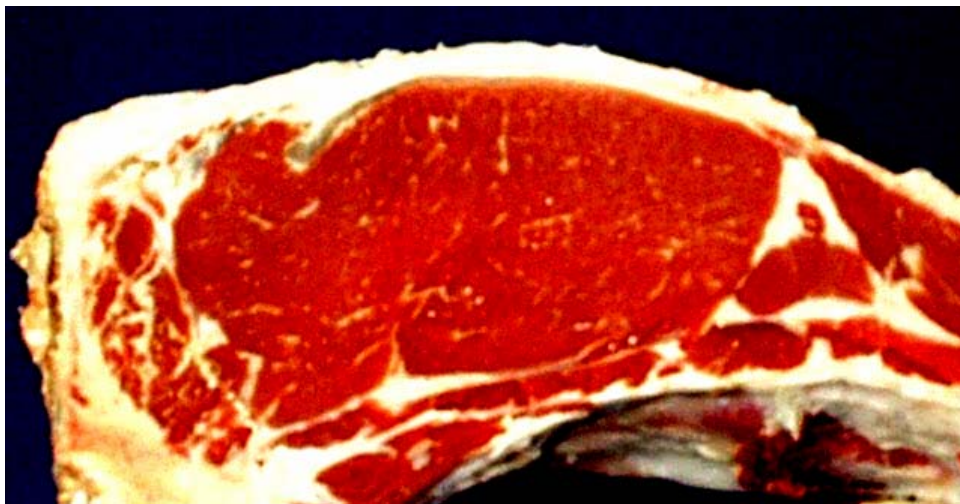
**Figure 2B.** 11-12<sup>th</sup> rib cross-sectional image



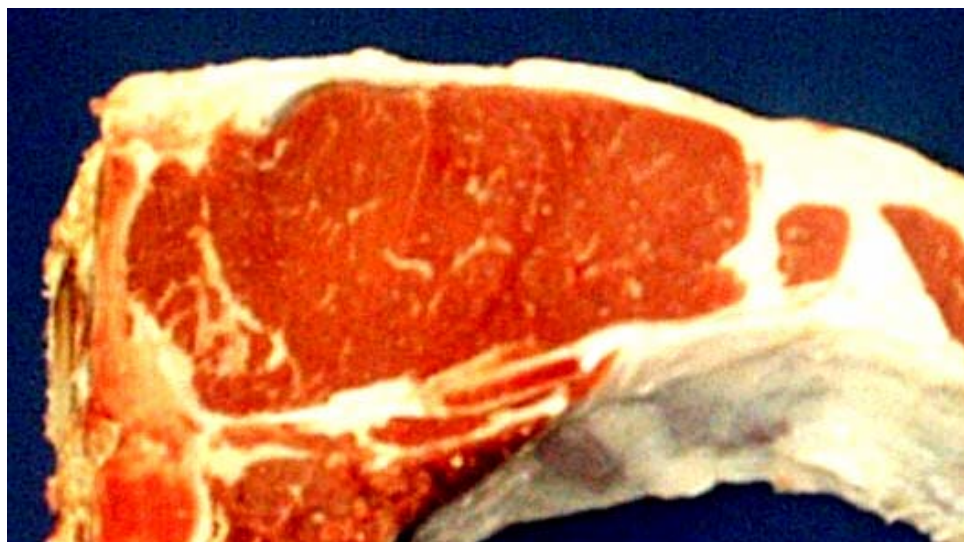**Figure 2C.** 10-11<sup>th</sup> rib cross-sectional image



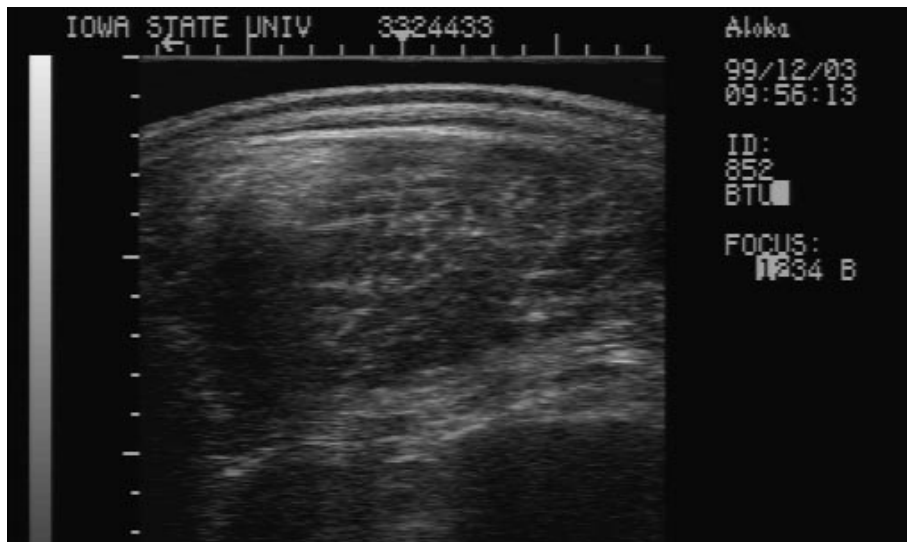
**Figure 3A.** 12<sup>th</sup>-13<sup>th</sup> rib carcass cross-section



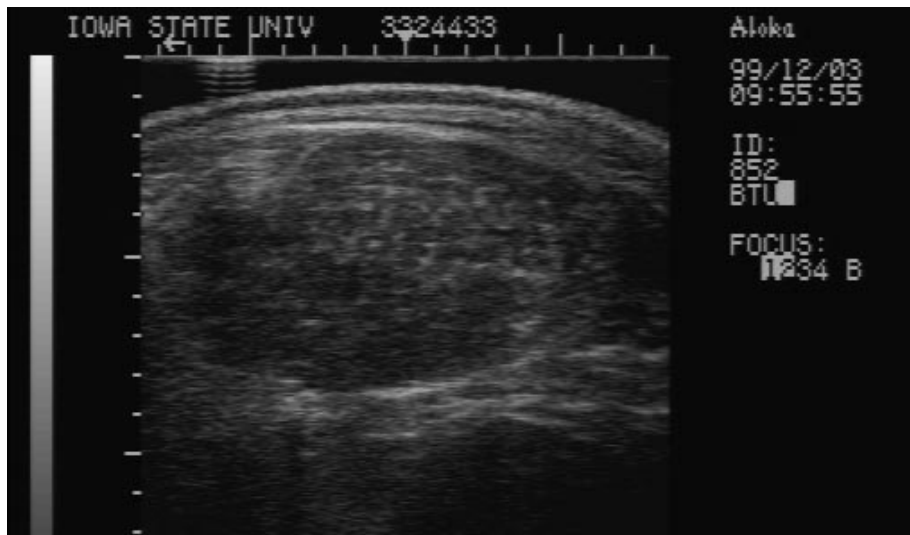
**Figure 3B.** 13<sup>th</sup>-1<sup>st</sup> lumbar carcass cross-section



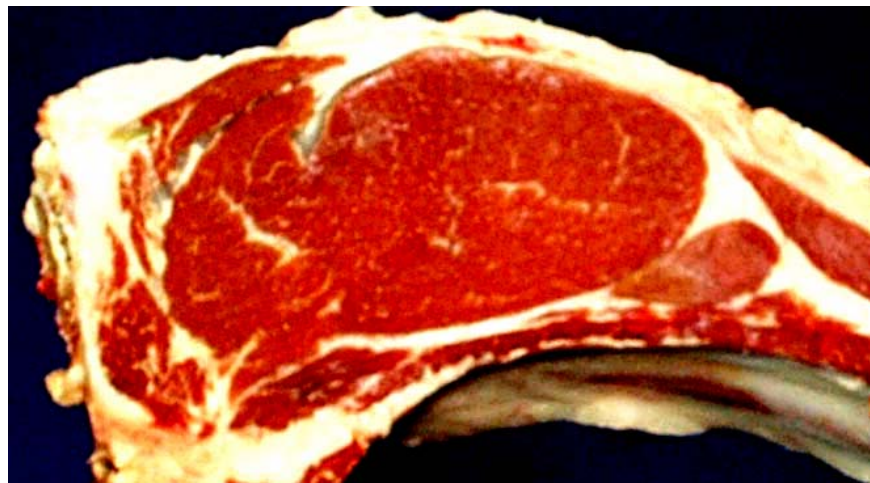
**Figure 3C.** 1<sup>st</sup>-2<sup>nd</sup> lumbar carcass cross-section



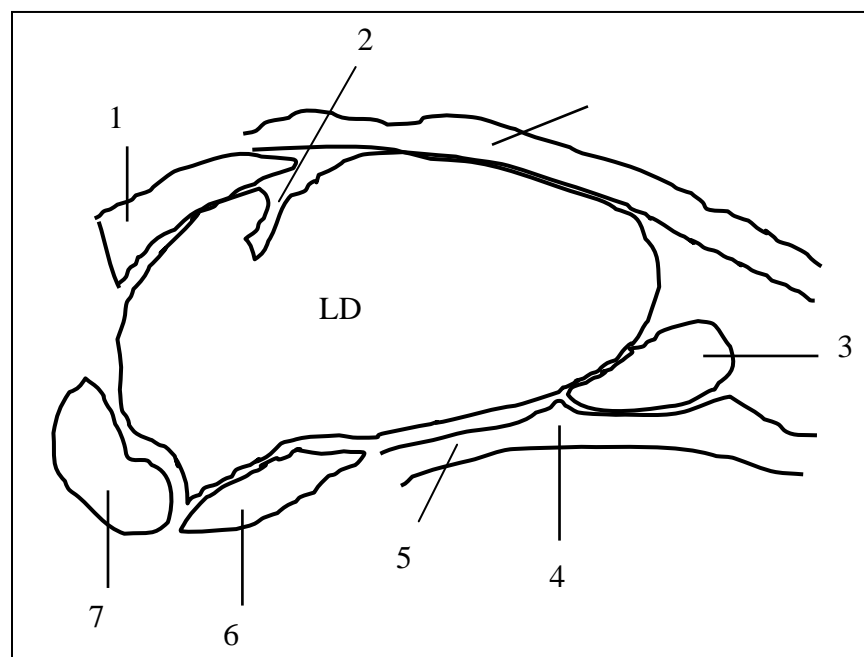
**Figure 4A.** 12-13<sup>th</sup> rib cross-sectional image



**Figure 4B.** 13<sup>th</sup>-1<sup>st</sup> lumbar cross-sectional image



**Figure 5A.** 12<sup>th</sup>-13<sup>th</sup> rib carcass cross-section



**Figure 5B** –Labeled outline of important landmarks at the 12-13<sup>th</sup> rib, where the carcass is broken into quarters.

1 – *Spinalis dorsi*

2 – Acorn Fat or the “Hook” of the ribeye

3 – *Longissimus costarum*

4 – “Break” in the intercostals

5 – Intercostal muscle boundaries or “Railroad Tracks”

6 – *Quadratus lumborum*

7 – *Multifidus dorsi*

F – Layer of the animal’s subcutaneous fat, measured at  $\frac{3}{4}$  the width of the ribeye

LD – *Longissimus dorsi* or “Ribeye”